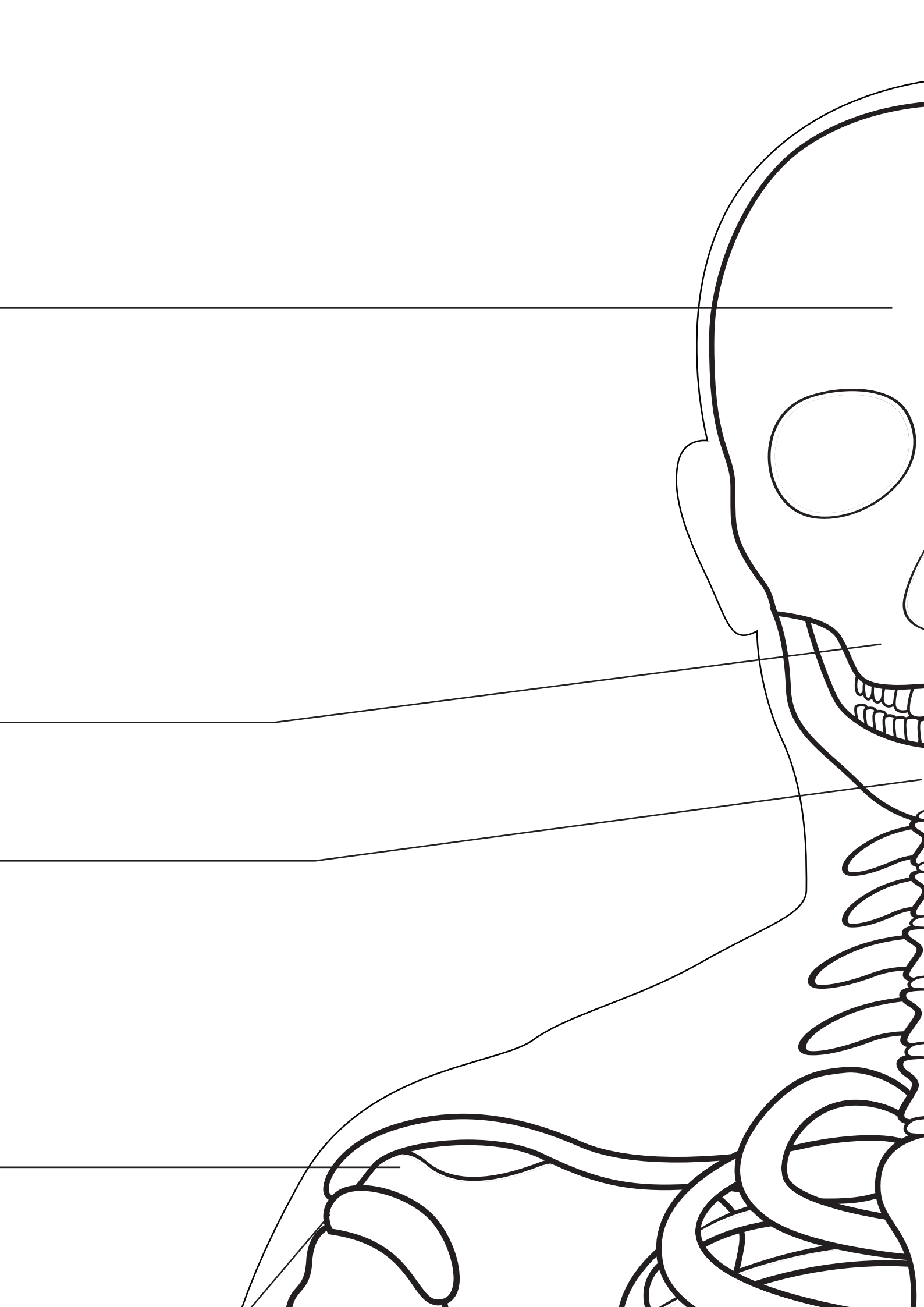


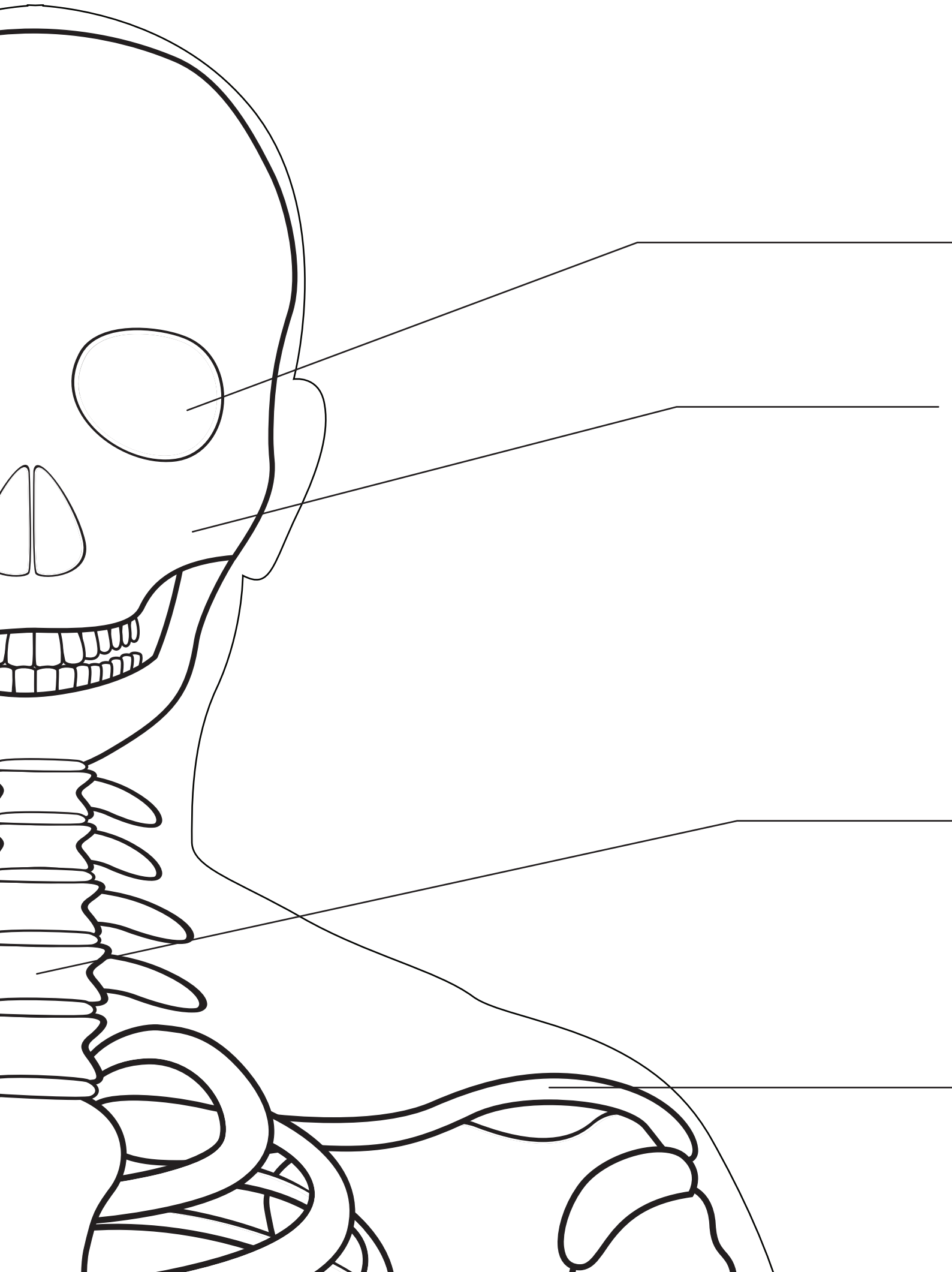
**Frontal Bone** \_\_\_\_\_

**Maxilla** \_\_\_\_\_

**Mandible** \_\_\_\_\_

**Acromion** \_\_\_\_\_





---

**Orbit**

**Zygomatic Bone**

---

**Cervical Spine**

---

**Clavicle**

**Coracoid Process**

**Scapula**



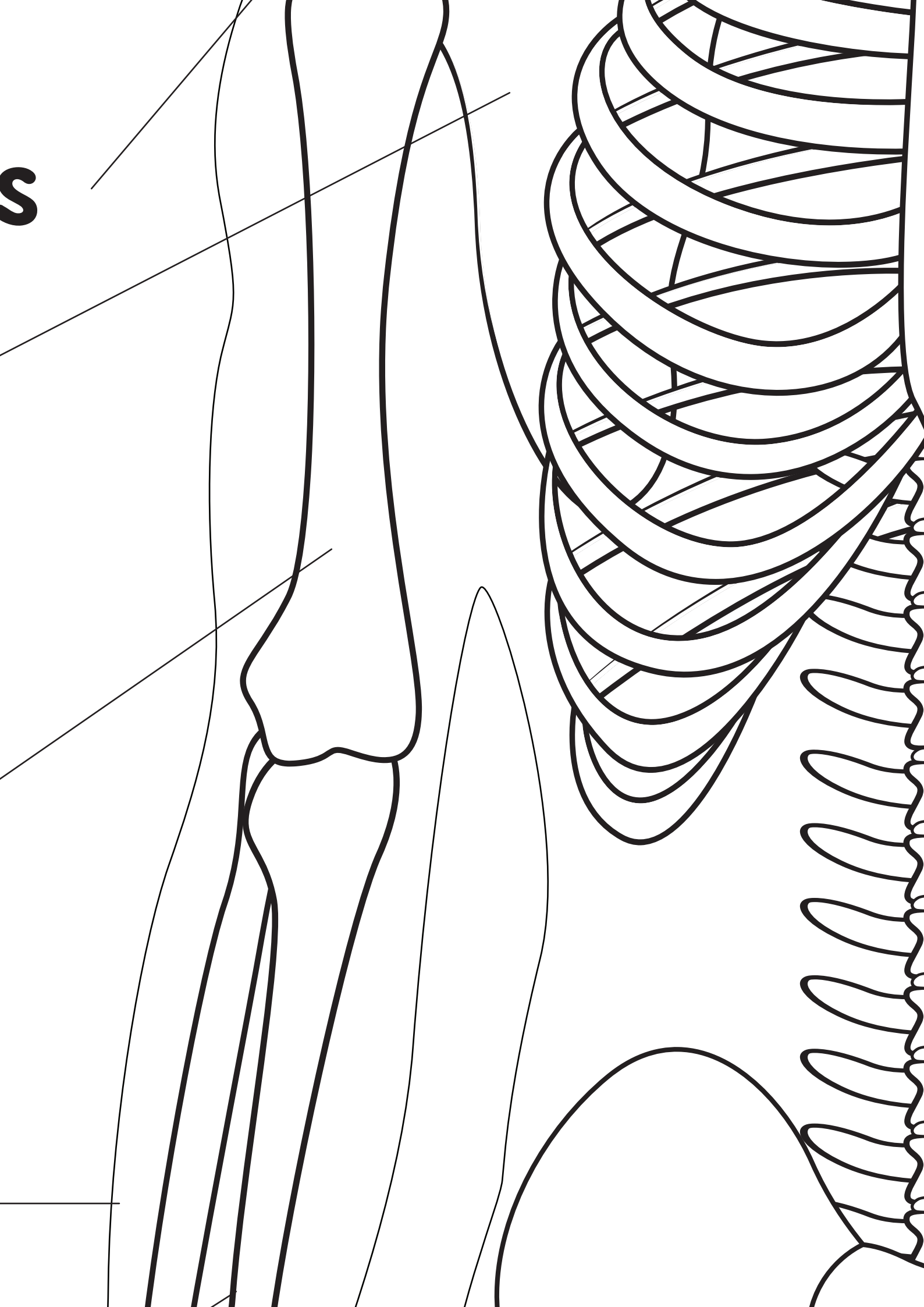
**Humerus**

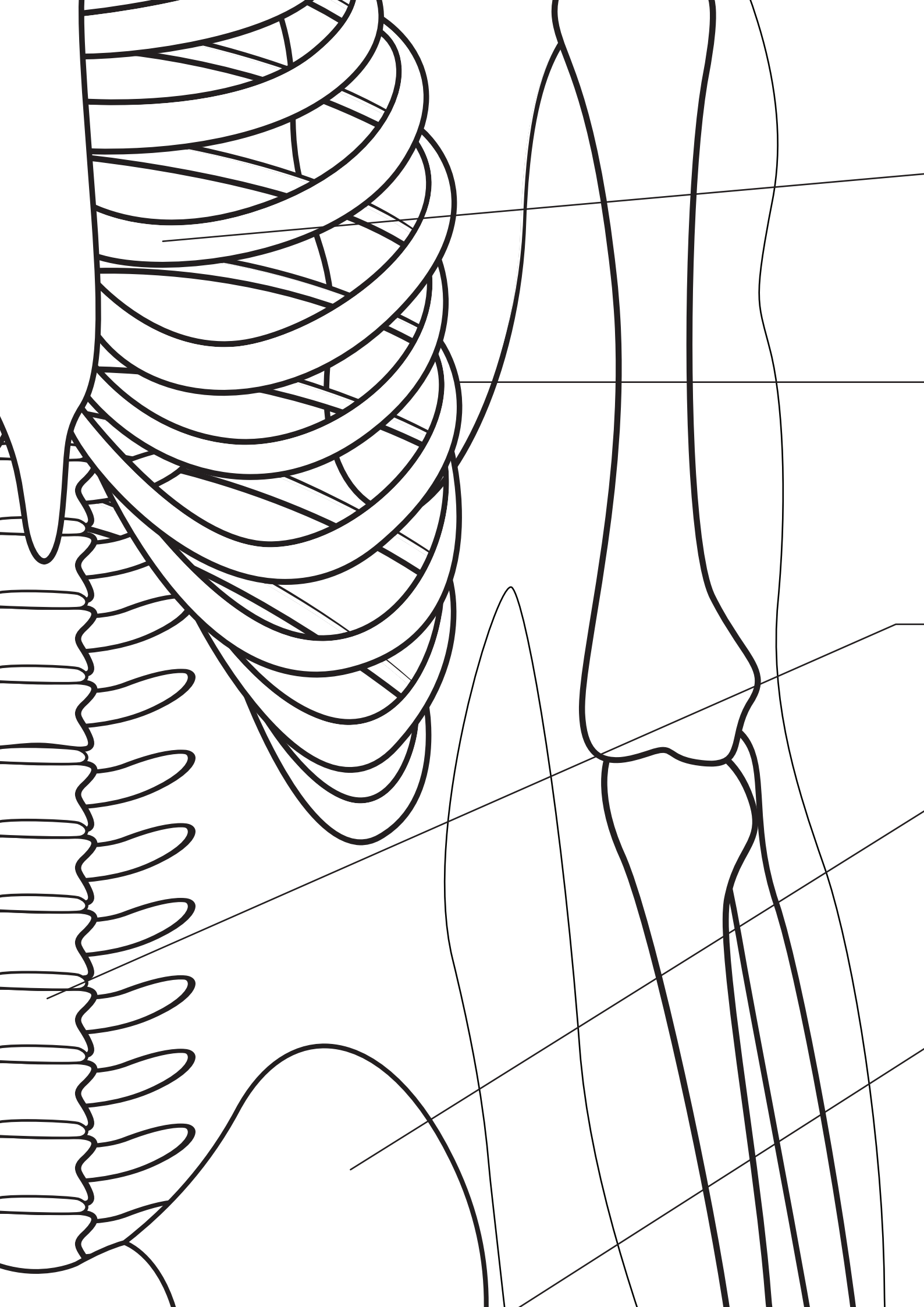


**Radius**



S







**Sternum**



**Ribs**



**Lumbar Spine**



**Ilium**



**Pubis**



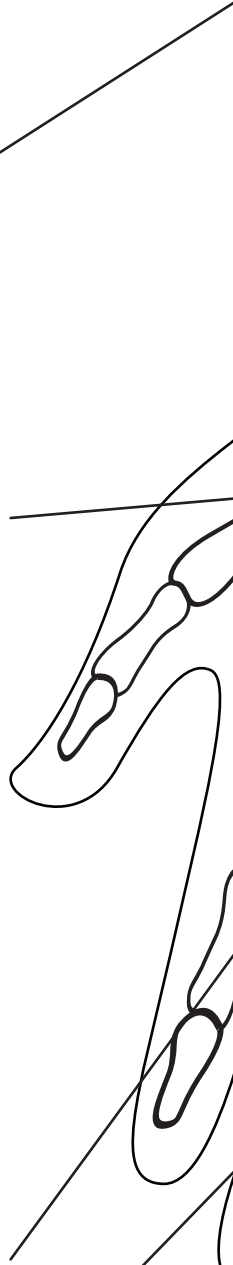
**Ulna**

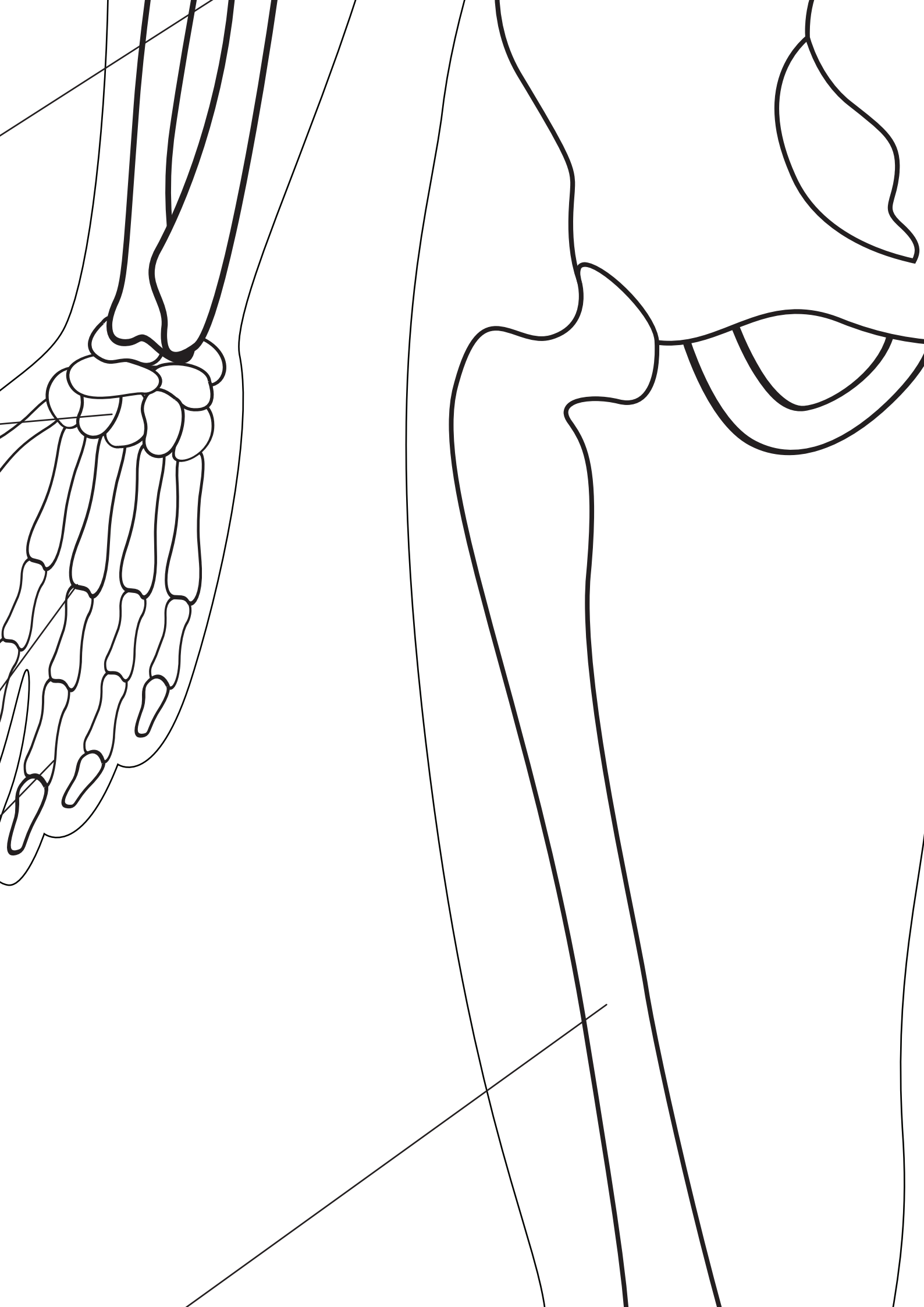
**Carpal Bones**

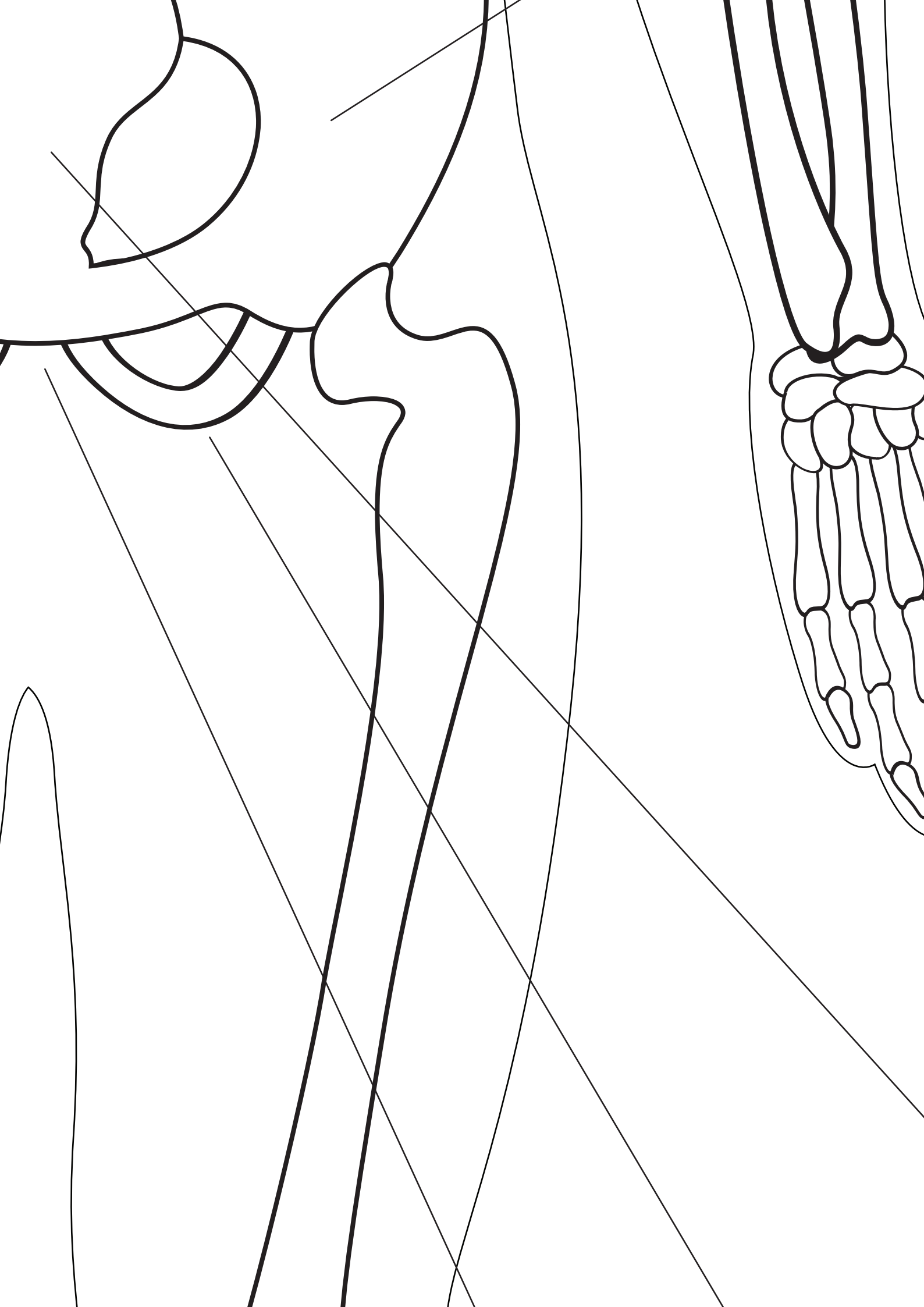
**Metacarpals**

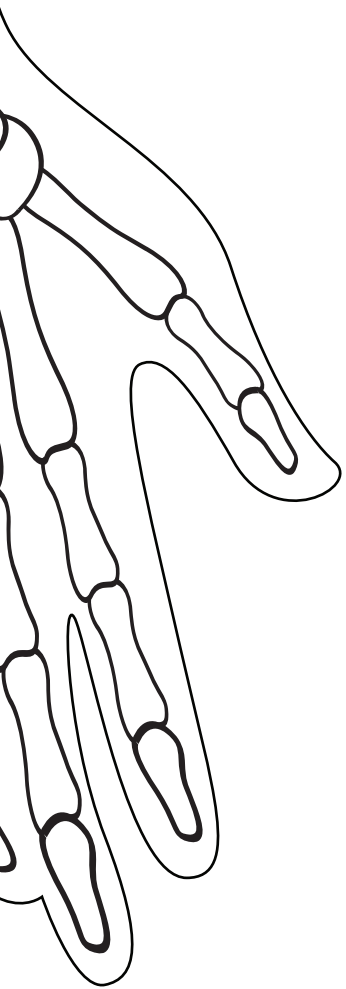
**Phalanges**

**Femur**









---

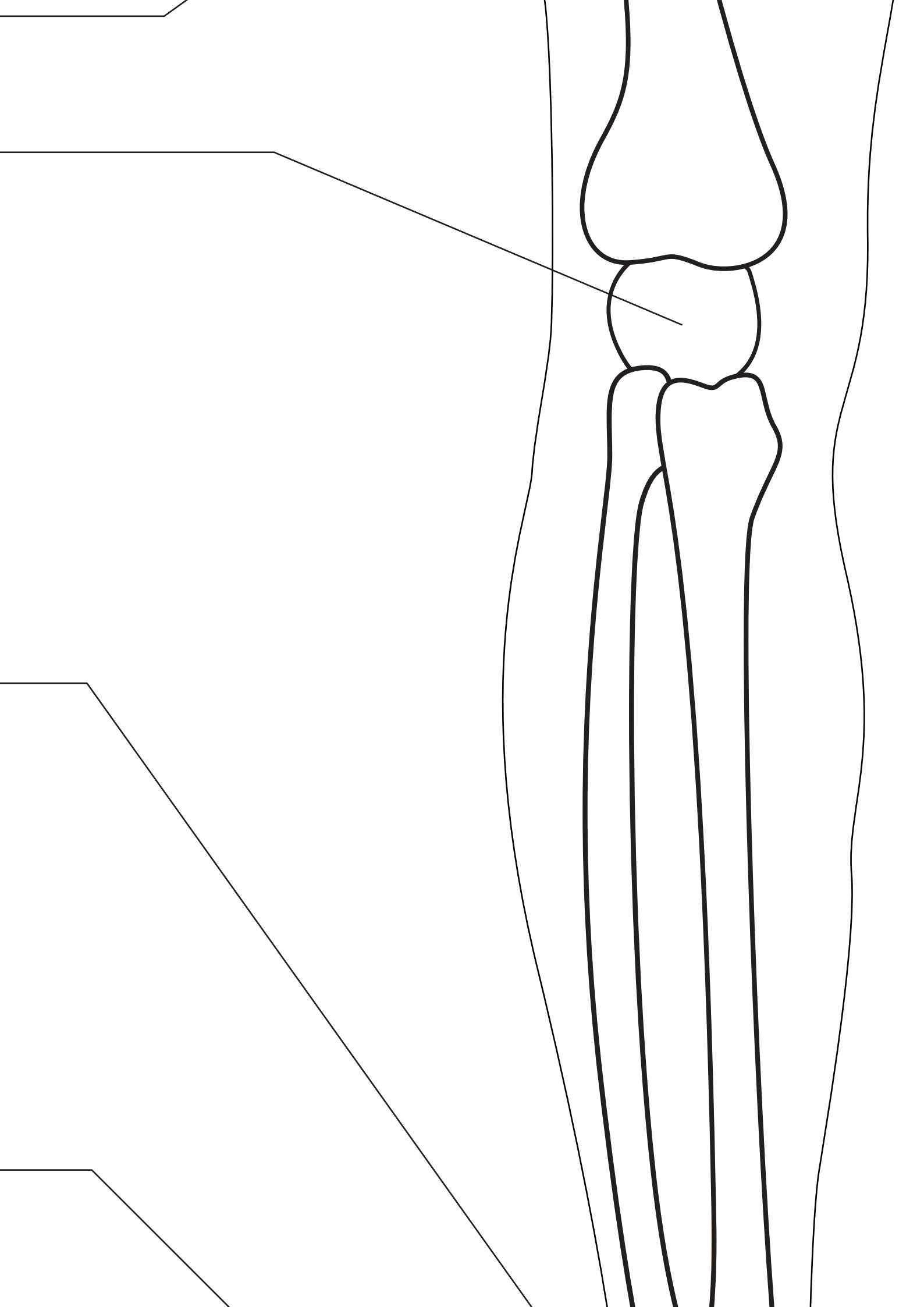
**Sacrum**

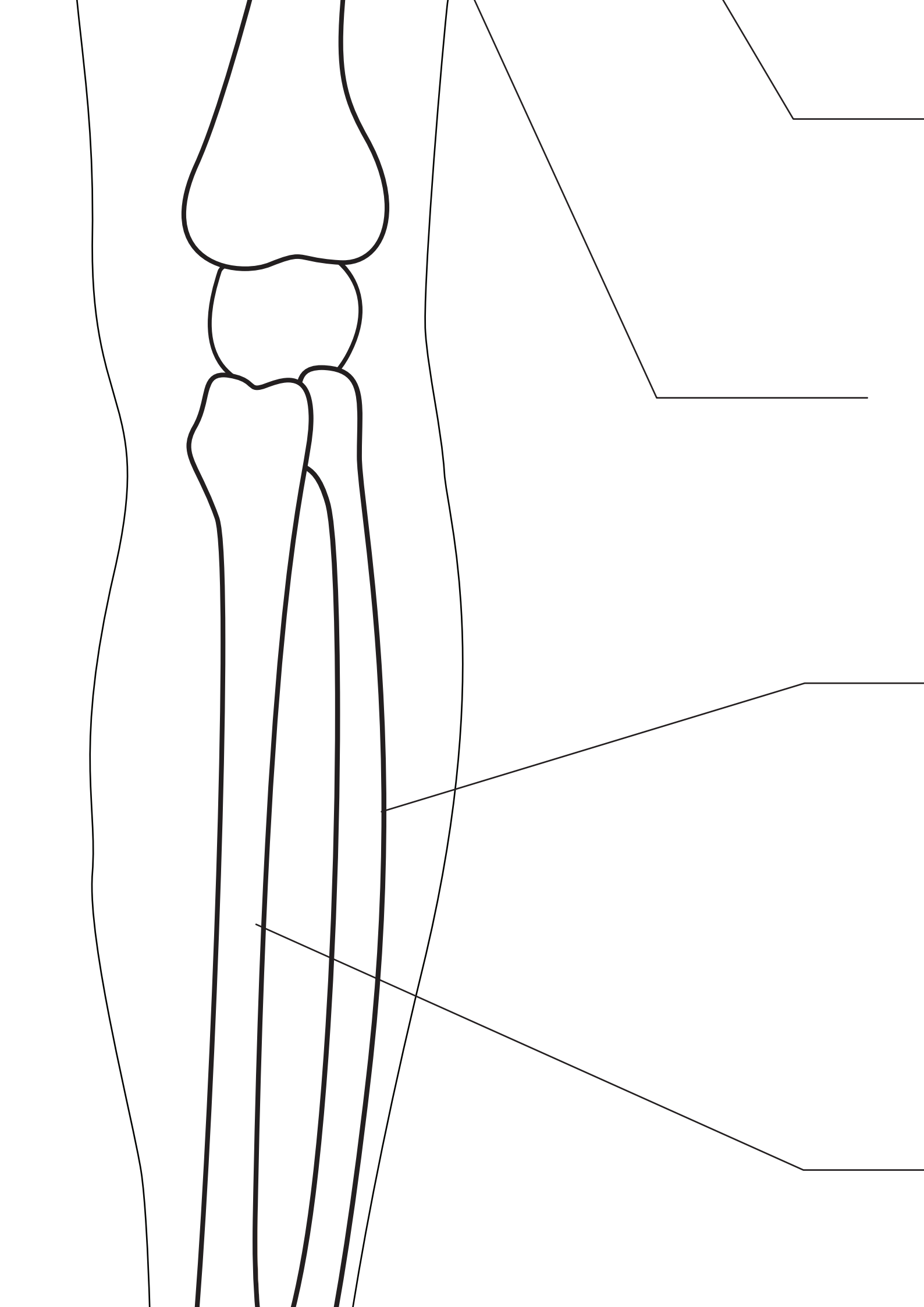
**femur** \_\_\_\_\_

**Patella** \_\_\_\_\_

**Tarsai Bones** \_\_\_\_\_

**Metatarsal** \_\_\_\_\_





---

**Ischium**

**Pubic Symphysis**

---

**Fibula**

---

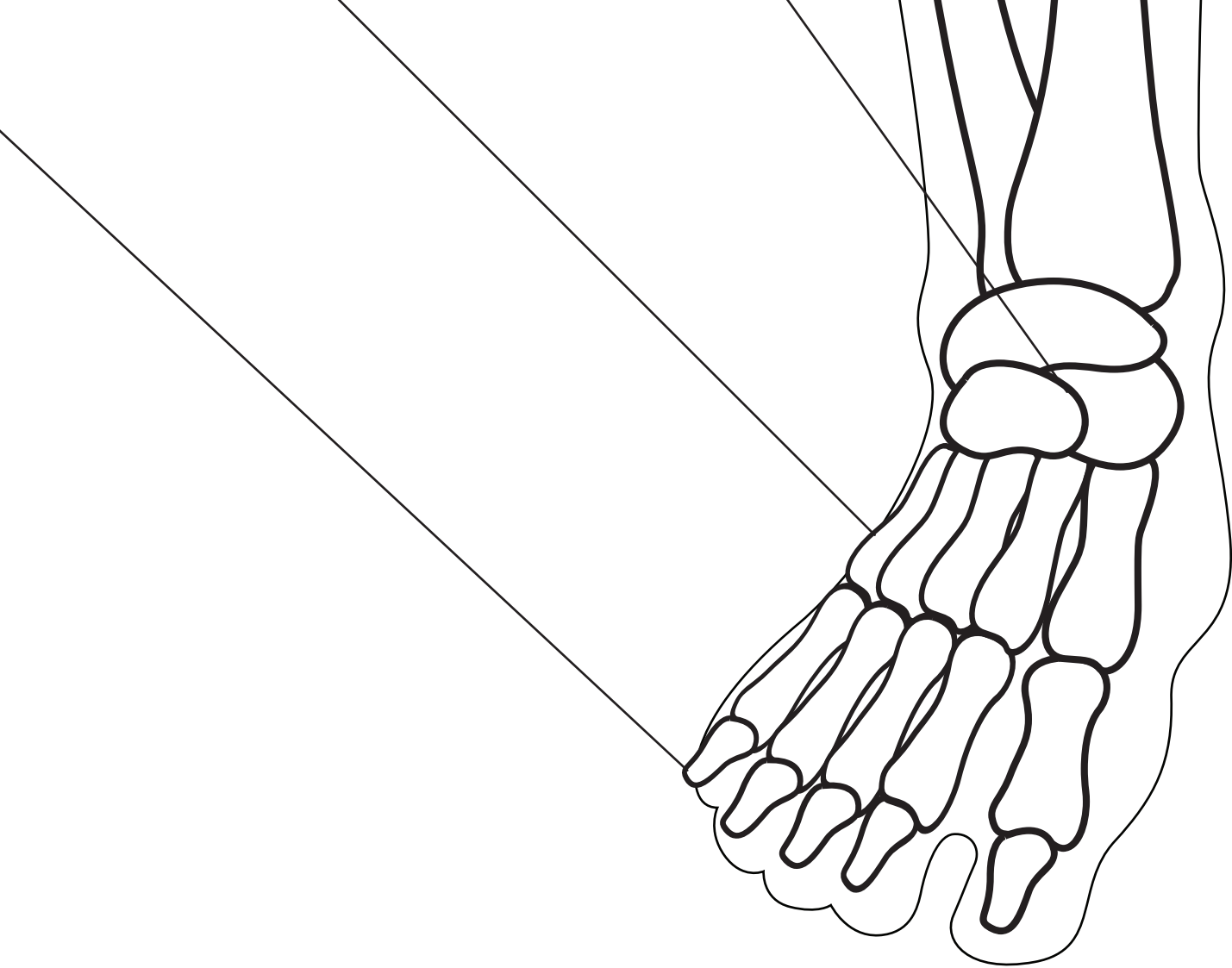
**Tibia**



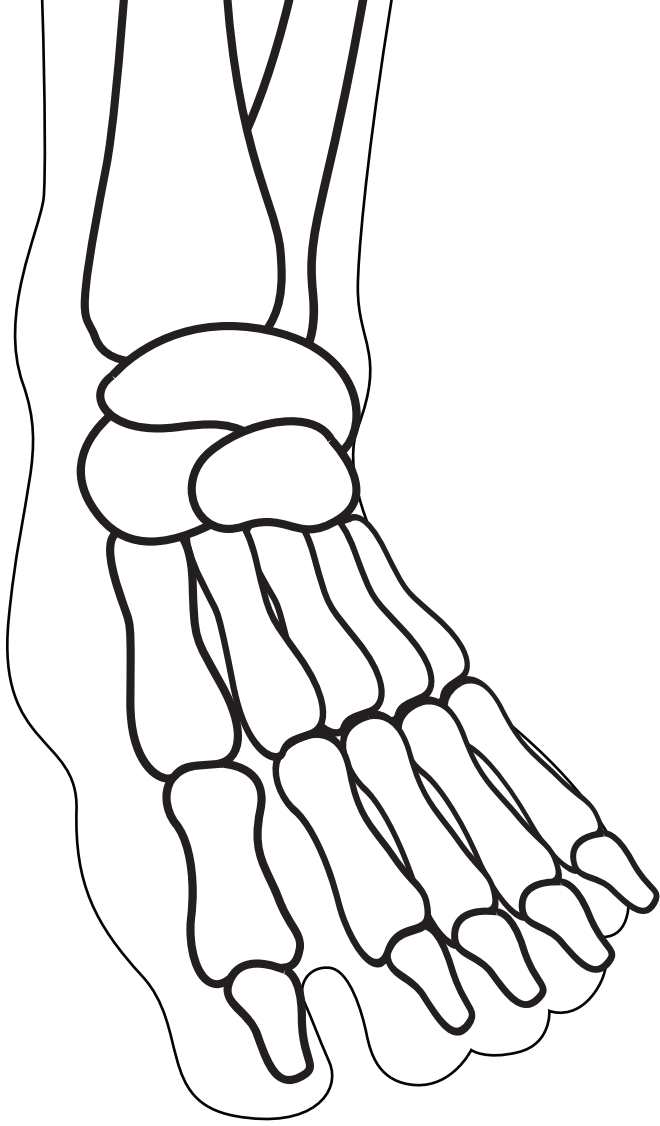
# Phalanges

---

# THE S



**SKELETON**



**AL SY**

**STEM**